

FEMALE. Age 61

13/6/12

Presenting Complaint

Haze RE - getting worse.

VA 6/19

No pain, no redness

Next HES 11/12 – needed advice earlier.

Going on holiday in 2/52

POH

HZV 2005 @ Iritis Predorte

Reviewed HES 12/12ly

Predforte - every 7 days for control of inflammation

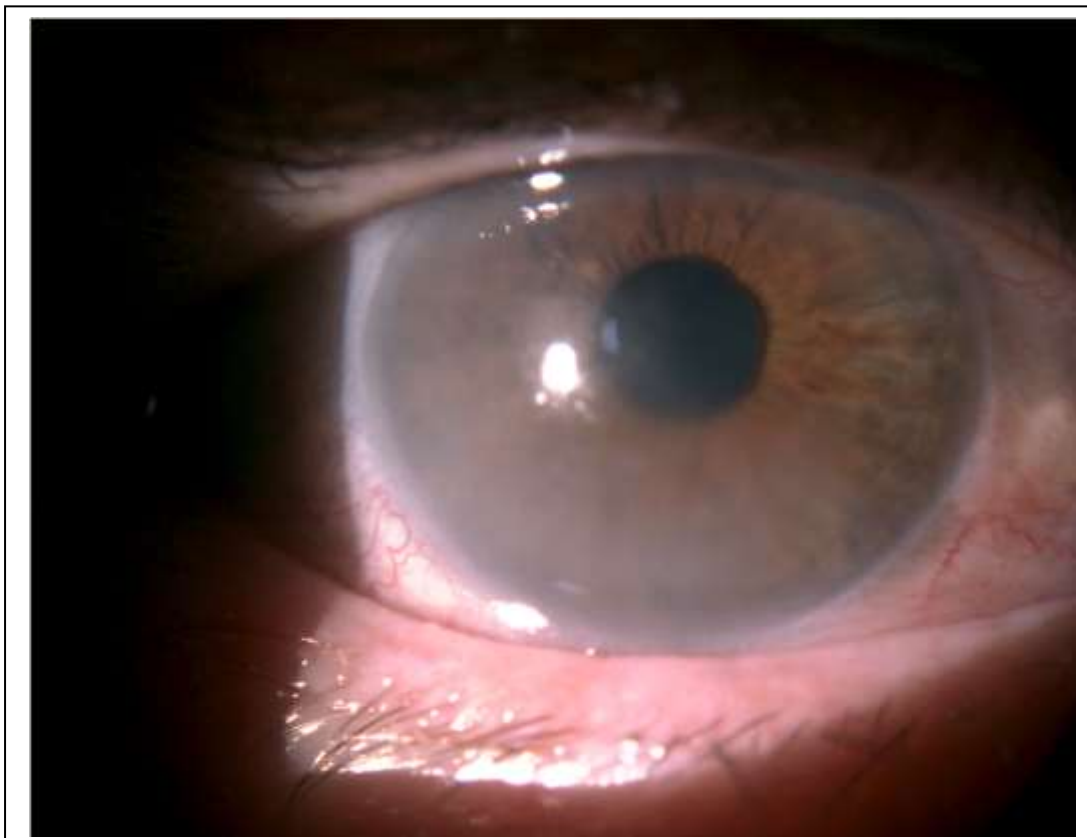
No IOP meds

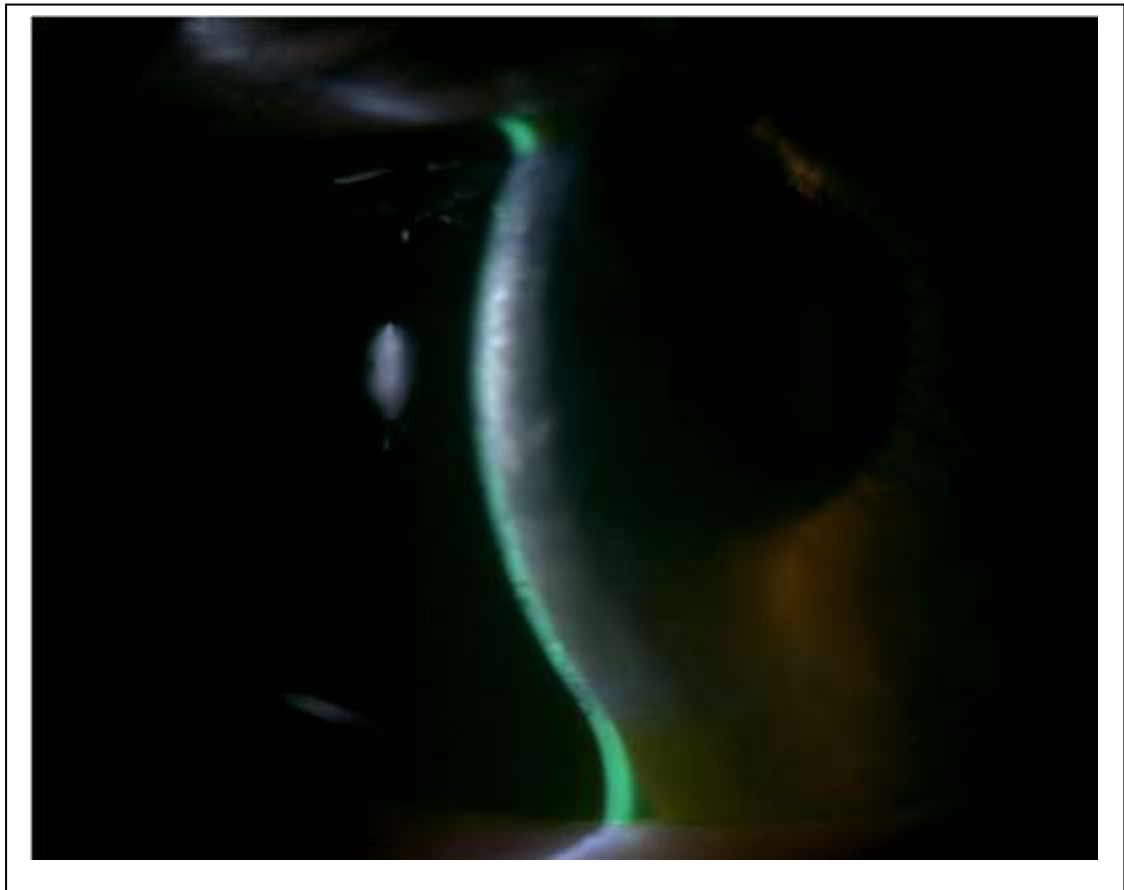
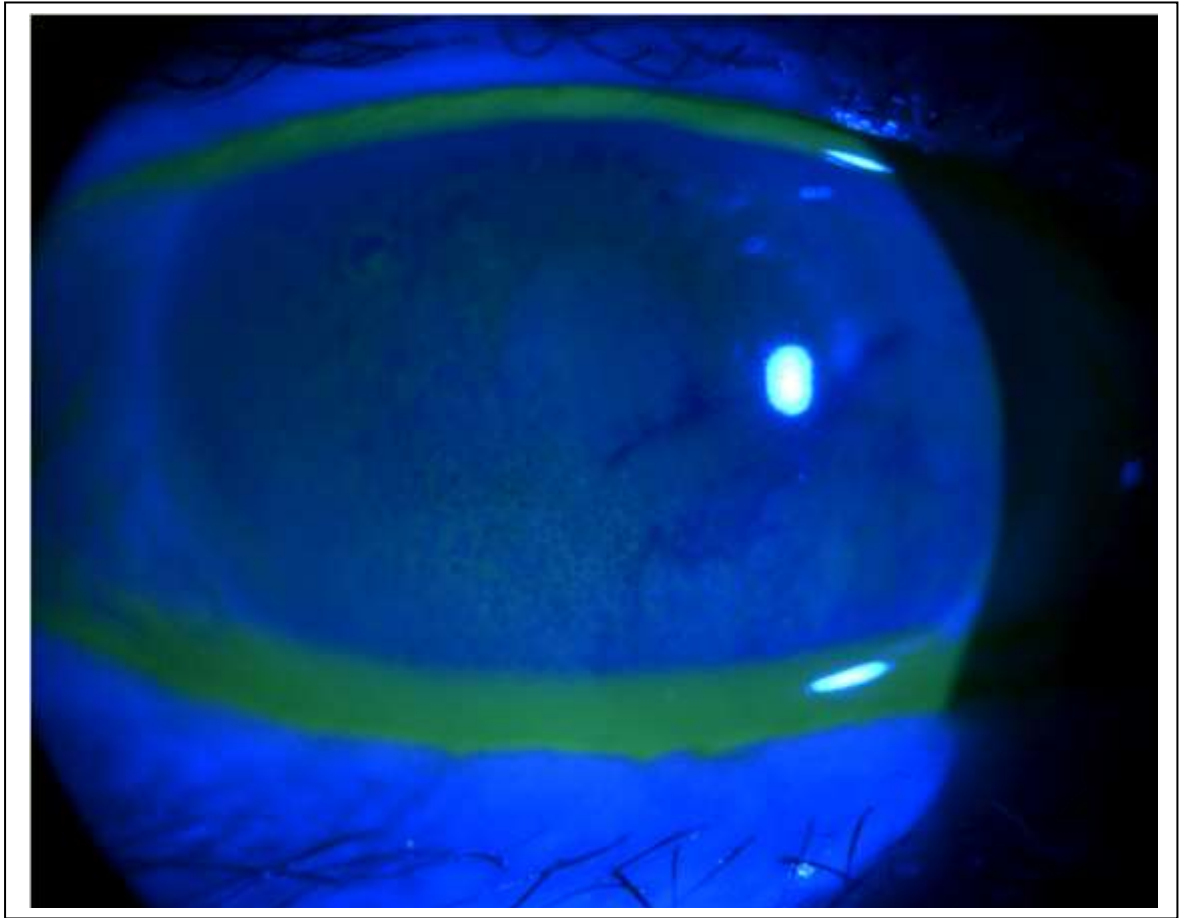
BP- Enalapril, Nifedipine

Allergies - penicillin, No Hayfever

Non-Smoker

Slit Lamp





## Treatment

Predforte q1h for 24/24 and review

Tapered very gradually

14/7/12 - Resolved - bid for 1/52 then 2X per week

Report this to HES? Dose at variance to theirs.

NOTES. Five types of Keratitis for both Simplex and Zoster

- 1) Infectious Epithelial Keratitis
  - 1) Vesicles
  - 2) Dendritic
  - 3) Geographic
    - 1) Scolloped borders
- 2) Interstitial Stromal Keratitis
  - 1) Immune Interstitial
- 3) Necrotising Keratitis
  - 1) Active viral stromal infection
- 4) Neurotrophic keratopathy
  - 1) Loss of innervation
  - 2) Smooth borders
- 5) Endotheliitis
  - 1) Primarily immune